Complex Cestode Infections

Christina Coyle, MD MS
Professor of Medicine and Pathology
Albert Einstein College of Medicine

1



2



3

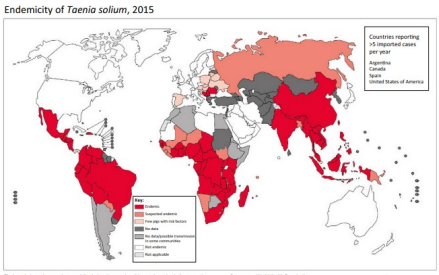

4

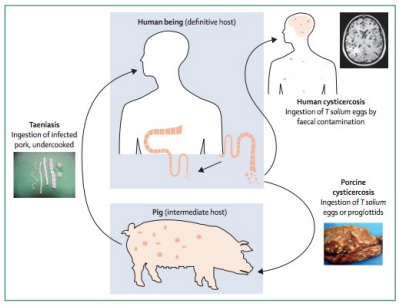

Figure 2: Lifecycle of *Taenia solium*
Reproduced and adapted from Garcia and colleagues.[46]

GARCIA et al. Lancet Neurol 2014:13:1202-15.

5

Clinical Presentation

- ►Location (Parenchymal, Extraparenchymal)
- ►Anatomic Location
- ► Burden of disease
- ►Host Response

6

Pleomorphic disease

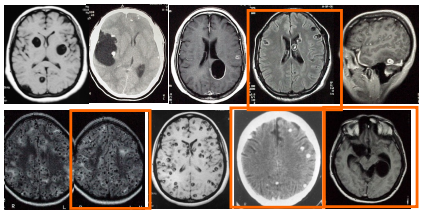

Courtesy Javiar Bustos

7

Parenchymal – Cystic Lesions

8

Evolution of Intraparenchymal cysts

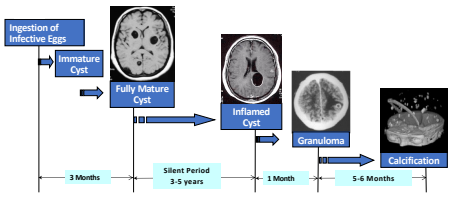

Courtesy Javiar Bustos

9

This is a 33 year old male recently immigrated from Puebla, Mexico . The patient presented to the Emergency Department with a grand mal seizure.

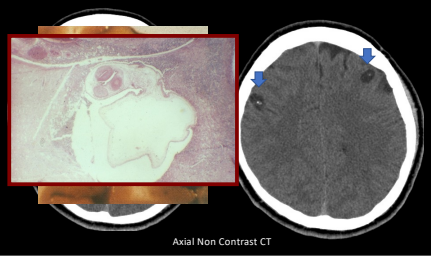

Axial Non Contrast CT

10

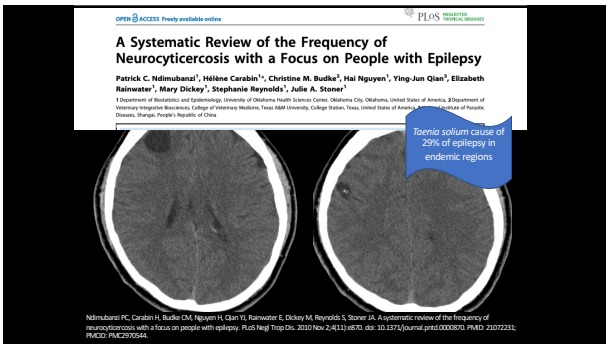

OPEN ACCESS Freely available online

PLoS NEGLECTED TROPICAL DISEASES

A Systematic Review of the Frequency of Neurocyticercosis with a Focus on People with Epilepsy

Patrick C. Ndimubanzi, Hélène Carabin, Christine M. Budke, Hai Nguyen, Ying-Jun Qian, Elizabeth Rainwater, Mary Dickey, Stephanie Reynolds, Julie A. Stoner

Taenia solium cause of 29% of epilepsy in endemic regions

Ndimubanzi PC, Carabin H, Budke CM, Nguyen H, Qian YJ, Rainwater E, Dickey M, Reynolds S, Stoner JA. A systematic review of the frequency of neurocysticercosis with a focus on people with epilepsy. PLoS Negl Trop Dis. 2010 Nov 2;4(11):e870. doi: 10.1371/journal.pntd.0000870. PMID: 21072231; PMCID: PMC2970544.

11

A 32 year old from Honduras presented with A grand mal seizure in 2004.
MRI shown at right.....

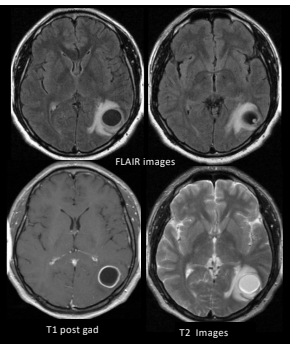

12

Patient has ongoing seizures since 2004.

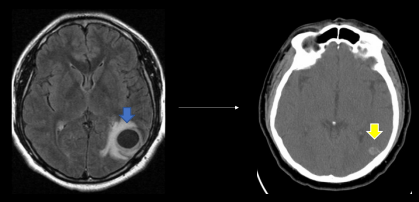

2004 5/2021

13

Evaluation of a Patient

- CT Scan – superior for calcifications
- MRI Scan – extraparenchymal lesions
- Serology- Western Blot
  - 94-98% sensitive, 100% specific
  - 30-70% sensitive
    - Single cyst or calcified lesion
  - Serum more sensitive than CSF
- Eye examination

DelBrutto et al. Neurology 2001 Jul 24:57:177-83
ASTMH/IDSA Guidelines,Clinical Infectious Diseases® 2018;66(8):e49–75

14

Evaluation of a Patient

- CT Scan – superior for calcifications
- MRI Scan – extraparenchymal lesions
- Serology- Western Blot
  - 94-98% sensitive, 100% specific
  - 30-70% sensitive
    - Single cyst or calcified lesion
  - Serum more sensitive than CSF
- Eye examination

Don't use Serum ELISA!

DelBrutto et al. Neurology 2001 Jul 24:57:177-83
ASTMH/IDSA Guidelines,Clinical Infectious Diseases® 2018;66(8):e49–75

15

A 30 year male born Cuenca, Ecuador. Immigrated 4 years ago and now presents with a seizure. An immunoblot for NCC is negative. Coronal MRI – T1 post gad images below.

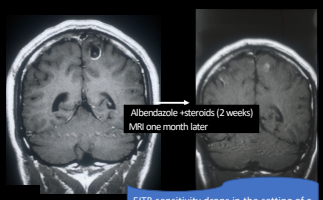

Albendazole +steroids (2 weeks)
MRI one month later

Serology- EITB
–94-98% sensitive, 100% specific
–30-70% sensitive
•Single cyst or calcified lesion
–Serum more sensitive than CSF

EITB sensitivity drops in the setting of a single lesion and calcified disease. Avoid ELISA !

16

Treatment- Viable Parenchymal Disease

17

Viable Neurocysticercosis

40 years old, Indian from the Punjab, immigrated to Canada 5 years ago. He presented to the ER for seizure- the episode was not witnessed. His exam in the ER was entirely normal, but the MRI and CT were done… He grew up in a village, and admits to being a passionate hunter of wild boar, which were fairly plentiful near the town…

Courtesy of Michael Libman M.D.
Division of Infectious Diseases (Director)
J.D. MacLean Centre for Tropical Diseases (Director)
McGill University Health Centre

18

19

ORIGINAL ARTICLE

A Trial of Antiparasitic Treatment to Reduce the Rate of Seizures Due to Cerebral Cysticercosis

Héctor H. Garcia, M.D., Ph.D., E. Javier Pretell, M.D., Robert H. Gilman, M.D., S. Manuel Martinez, M.D., Lawrence H. Moulton, Ph.D., Oscar H. Del Brutto, M.D., Gerardo Herrera, M.D., Carlton A.W. Evans, M.D., Ph.D., and Armando E. Gonzalez, D.V.M., Ph.D., for the Cysticercosis Working Group in Peru*

Table 3. Number of Seizures during Follow-up in the Two Study Groups.

Variable	No. of Patients		No. of Seizures		Efficacy (95% CI)[a]		P Value	
	Albendazole (N=57)	Placebo (N=59)	Albendazole (N=57)	Placebo (N=59)	Unadjusted	Adjusted†	Unadjusted	Adjusted†
					percent			
Partial seizures‡								
Month 1						—§	0.42	—§
Months 2–12						43 (–28 to 75)	0.30	0.17
Months 13–30	10				21 (–249 to 82)	–13 (–387 to 74)	0.76	0.87
Months 2–30	19	16	171	296	41 (–124 to 84)	34 (–79 to 76)	0.44	0.41
Seizures with generalization¶								
Month 1	7	2	7	5	–45 (–681 to 73)	–41 (–409 to 61)	0.67	0.60
Months 2–12	8	16	12	41	70 (9 to 90)	69 (15 to 88)	0.03	0.02
Months 13–30	7	17	10	27	62 (13 to 84)	62 (8 to 84)	0.02	0.03
Months 2–30	13	22	22	68	67 (20 to 86)	67 (32 to 84)	0.01	0.003

10 days of albendazole PLUS steroids vs Steroids alone

20

ORIGINAL ARTICLE

A Trial of Antiparasitic Treatment to Reduce the Rate of Seizures Due to Cerebral Cysticercosis

Héctor H. Garcia, M.D., Ph.D., E. Javier Pretell, M.D., Robert H. Gilman, M.D., S. Manuel Martinez, M.D., Lawrence H. Moulton, Ph.D., Oscar H. Del Brutto, M.D., Gerardo Herrera, M.D., Carlton A.W. Evans, M.D., Ph.D., and Armando E. Gonzalez, D.V.M., Ph.D., for the Cysticercosis Working Group in Peru*

Table 3. Number of Seizures during Follow-up in the Two Study Groups.

Variable	No. of Patients		No. of Seizures		Efficacy (95% CI)[a]		P Value	
	Albendazole (N=57)	Placebo (N=59)	Albendazole (N=57)	Placebo (N=59)	Unadjusted	Adjusted†	Unadjusted	Adjusted†
					percent			
Partial seizures‡								
Month 1	12	8	35	67	46 (–141 to 88)	—§	0.42	—§
Months 2–12	18	15	100	204	49 (–81 to 86)	43 (–28 to 75)	0.30	0.17
Months 13–30	10	9	71	92	21 (–249 to 82)	–13 (–387 to 74)	0.76	0.87
Months 2–30	19	16	171	296	41 (–124 to 84)	34 (–79 to 76)	0.44	0.41
Seizures with generalization¶								
Month 1	7	2	7	5	–45 (–681 to 73)	–41 (–409 to 61)	0.67	0.60
Months 2–12	8	16	12	41	70 (9 to 90)	69 (15 to 88)	0.03	0.02
Months 13–30	7	17	10	27	62 (13 to 84)	62 (8 to 84)	0.02	0.03
Months 2–30	13	22	22	68	67 (20 to 86)	67 (32 to 84)	0.01	0.003

21

ORIGINAL ARTICLE

A Trial of Antiparasitic Treatment to Reduce the Rate of Seizures Due to Cerebral Cysticercosis

Héctor H. Garcia, M.D., Ph.D., E. Javier Pretell, M.D., Robert H. Gilman, M.D., S. Manuel Martinez, M.D., Lawrence H. Moulton, Ph.D., Oscar H. Del Brutto, M.D., Gerardo Herrera, M.D., Carlton A.W. Evans, M.D., Ph.D., and Armando E. Gonzalez, D.V.M., Ph.D., for the Cysticercosis Working Group in Peru*

Table 3. Number of Seizures during Follow-up in the Two Study Groups.

Variable	No. of Patients		No. of Seizures		Efficacy (95% CI)[a]		P Value	
	Albendazole (N=57)	Placebo (N=59)	Albendazole (N=57)	Placebo (N=59)	Unadjusted	Adjusted†	Unadjusted	Adjusted†
					percent			
Partial seizures‡								
Month 1							0.42	—§
Months 2–12						28 to 75)	0.30	0.17
Months 13–30						–387 to 74)	0.76	0.87
Months 2–30						to 76)	0.44	0.41
Seizures with generalization¶								
Month 1						–41 (–409 to 61)	0.67	0.60
Months 2–12	8					69 (15 to 88)	0.03	0.02
Months 13–30	7	17	10	27	62 (13 to 84)	62 (8 to 84)	0.02	0.03
Months 2–30	13	22	22	68	67 (20 to 86)	67 (32 to 84)	0.01	0.003

First Month No difference – probably due to abrupt stop of steroids
Established Albendazole as therapy for NCC

Garcia HH. et al NEJM 2004; 350:249-258

22

There were still treatment failures.
What about dual therapy for parenchymal NCC?

23

MRI response to Albendazole (15 or 22.5 mg/kg/d) alone or with Praziquantel in patients with >2 viable cysticerci

	ABZ + PZQ (n=39)	ABZ 15 mg/kg/d(n=41)	ABZ 22.5 mg/kg/d (n=38)	*P*
Mean cysts Baseline	9.0	6.8	7.1	0.25
Mean 180 d	0.6	5.3	3.7	<.001
Cysts resolved	94%	21%	48%	<.001
Patient cured	68%	5%	25%	<.001

Garcia et al Lancet Infect Dis 2014

24

MRI response to Albendazole (15 or 22.5 mg/kg/d) alone or with Praziquantel in patients with >2 viable cysticerci

No improved efficacy in single lesions
Improved resolution on MRI, but only if >2 cysts
Fewer seizures in those with resolution

Garcia et al Lancet Infect Dis 2014

25

Guidelines: Role of anti-parasitic drugs in viable parenchymal neurocysticercosis?

Antiparasitic drugs in ALL patients w/ viable NCC

1-2 Viable cysts Recommendation:
Albendazole monotherapy
> 2 Viable cysts Recommendation:
Dual therapy with albendazole and praziquantel

Clinical Infectious Diseases® 2018;66(8):e49–75

26

27

Guidelines: Role of anti-parasitic drugs/anti-inflammatory therapy in viable parenchymal neurocysticercosis?

Always use corticosteroids for inflammatory response.
Enhanced dosing leads to less neurologic outcomes.

Clinical Infectious Diseases® 2018;66(8):e49–75

28

LENGTH ORIGINAL RESEARCH

Enhanced steroid dosing reduces seizures during antiparasitic treatment for cysticercosis and early after

*†‡§Hector H. Garcia, *Isidro Gonzales, ‖¶Andrea G. Lescano, ‖Javier A. Bustos, #E. Javier Pretell, *Herbert Saavedra, **Theodore E. Nash for The Cysticercosis Working Group in Peru

Epilepsia, 55(9):1452–1459, 2014
doi: 10.1111/epi.12739

- Open-label randomized trial comparing 6 mg dexamethasone for 10 days with 8 mg for 28 days followed by a 2 week taper (enhanced steroids).
- Follow up of seizures
- Increased dexamethasone dosing results in fewer seizures

Nash et al. 2012. Nat Rev Neurol; 7(10):584-594.

29

IDSA/ASTMH guidelines
Summary Parenchymal Neurocysticercosis

- **1-2 Viable cysts Recommendation:**
- Albendazole monotherapy
- **> 2 Viable cysts Recommendation:**
- Dual therapy with albendazole and praziquantel
- **Length of therapy** - 2 weeks (4 weeks)
- **Always use steroids and be generous… host inflammatory control is important**
  - 8 mg for 28 days followed by a 2 week taper

Clinical Infectious Diseases® 2018;66(8):e49–75

30

Calcified Parenchymal NCC

- Common cause of seizures and epilepsy
- CT shows calcification, Edema and/or enhancement on MRI
- Seizures often recur (epilepsy)

31

Calcified Case of NCC

78M from Ecuador admitted with right sided hemiparesis after Pfizer COVID vaccine.

32

CT HEAD AXIAL 06.11.22

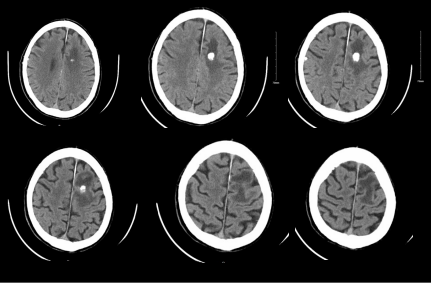

33

CT HEAD AXIAL 06.11.22

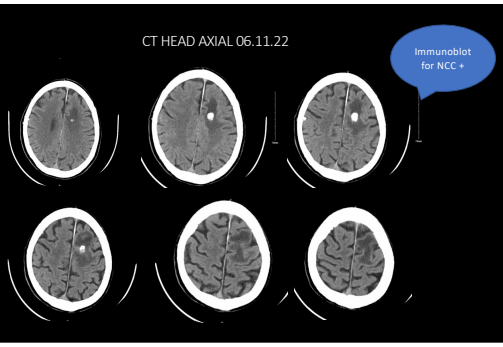

34

AXIAL FLAIR

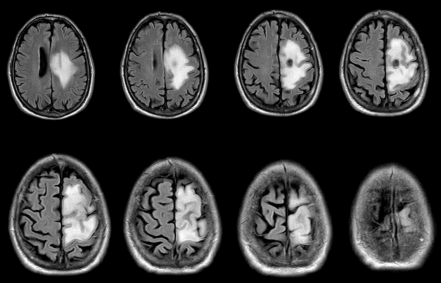

35

T1W AXIAL POST GAD

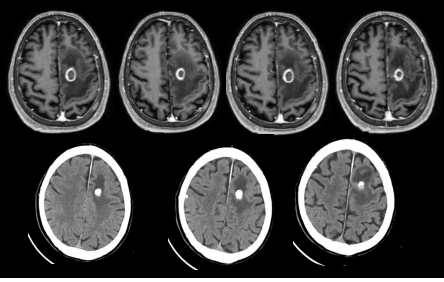

36

How do we manage perilesional edema around a calcified lesion?

- No antiparasitic treatment
- Try to avoid steroids – rebound edema will occur as you come off
- In cases like this, use steroids, BUT slow taper
- Recurrent cases occur
  - Eternacept, methotrexate
  - Removal of calcification

37

Taenia solium Granulomas with Perilesional Edema

- *Taenia solium* cause of 29% of epilepsy in endemic regions
- Epilepsy is mostly associated with calcified granulomas
  - At the time of seizures 50% of those with calcifications demonstrate transient surrounding perilesional edema.
  - Whether the edema is a consequence of seizure or a result of host inflammation directed against parasite antigens
  - Always enhance on post-contrast MRI images.

Perilesional brain oedema and seizure activity in patients with calcified neurocysticercosis: a Prospective cohort and nested-case control study. Lancet Neurol 2008 Dec;7(12):1099-105

38

Seizure Recurrence in Calcific Parenchymal NCC

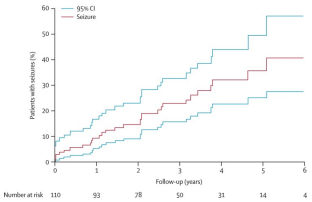

•36% with seizure recurrence within 5 yrs

Nash et al. Lancet Neurol. 2008;7:1099

39

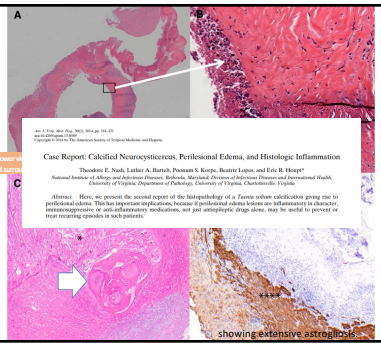

40

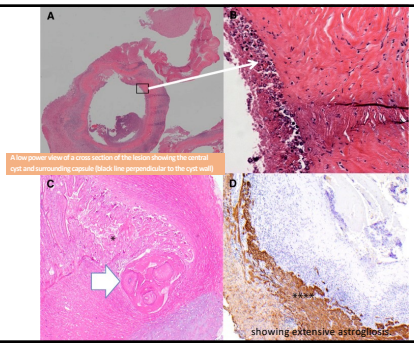

41

Calcified Neurocysticercosis Recommendations

- Subset of calcifications incite inflammation
- No antiparasitic drugs
- Risk of recurrent seizures
- Treat seizures with AEDs
- Perilesional edema, caution on use of steroids (control symptoms, trigger episodes)
- Always do a susceptibility weighted sequence on MRI (SWI and SWAN)

42

Cases out of the box

43

Giant Parenchymal Cyst

44

A 47 year old from El Salvador with a migraine headache – 2015- MRI cyst – NO treatment offered!!

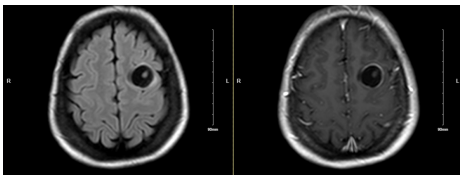

MRI
FLAIR Images

MRI
T1 post - gad

45

2016 One year Later …. She presents to another hospital with somnolence and hemiparesis. Cyst has gotten much bigger! Lots of edema.

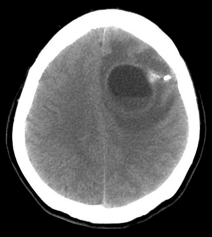

Axial CT scan

46

Patient was treated with albendazole and steroids for months…. Will this calcify???

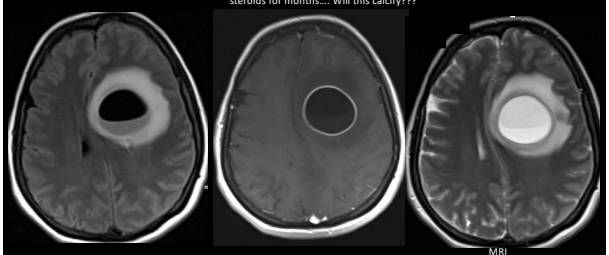

Axial FLAIR

MRI
Axial
T1 Post Gad

MRI
Axial
T2

47

38% of Cysts will Calcify
Risk Factors for Calcification After Treatment with Antiparasitics

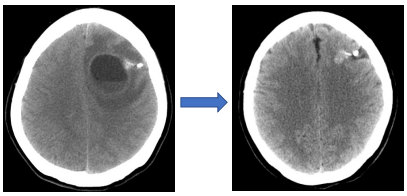

2016

2017
Asymptomatic

Predictors for calcification
Cysts larger than 14 mm
Cysts with edema at baseline

Clin Infect Dis. 2021 Nov 2;73(9):e2592-e2600. doi: 10.1093/cid/ciaa784.

48

49

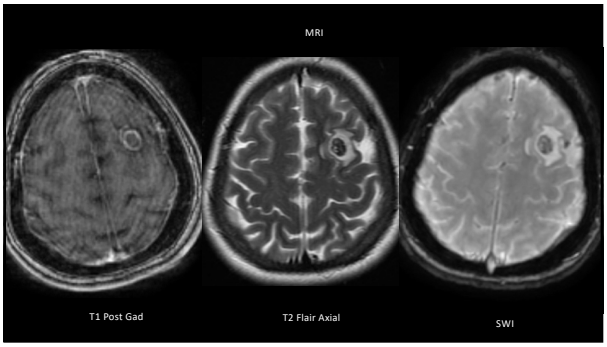

50

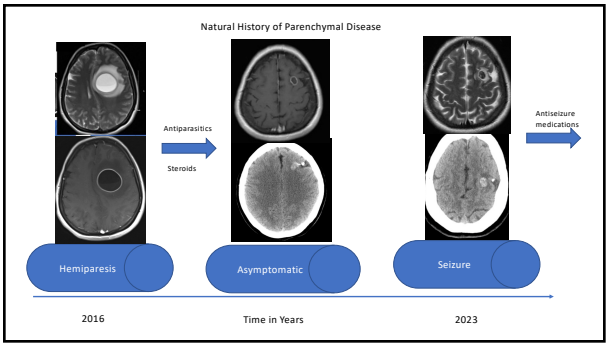

51

Cysticercotic Encephalitis

52

HISTORY

- A 42-year-old gentleman from Northern India presented with a 2-year history of slowly progressive dementia. He also noticed multiple painless non-pruritic slow growing nodular lesions over his trunk, extremities, forehead and tongue for the past 1 year.
- He did not have headache, vomiting, fever, seizures or focal neurological deficits. There was no loss of weight or constitutional symptoms.

Courtesy of Priscilla Rupali
Christian Medical Center
Vellore India

53

CLINICAL IMAGES

54

CLINICAL IMAGES

55

MR IMAGES

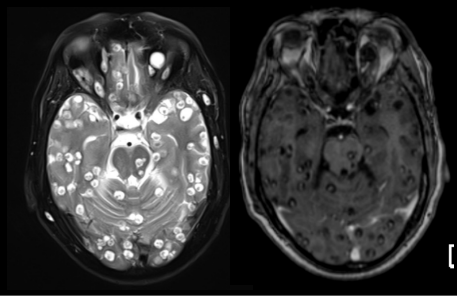

56

MR IMAGES

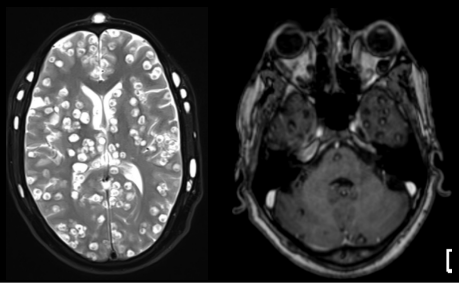

57

MR IMAGES

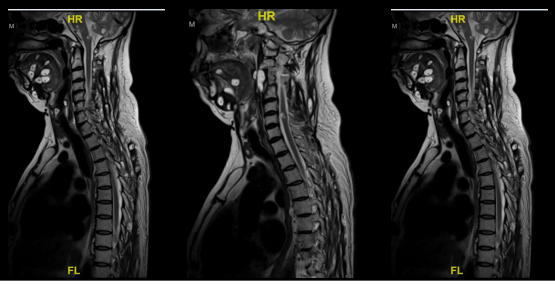

58

Am. J. Trop. Med. Hyg., 100(3), 2019, pp. 609–616

The American Society of Tropical Medicine and Hygiene

Etanercept to Control Inflammation in the Treatment of Complicated Neurocysticercosis

Theodore E. Nash,1* JeanAnne M. Ware,1 Christina M. Coyle,2 and Siddhartha Mahanty1
1Laboratory of Parasitic Diseases, National Institutes of Allergy and Infectious Diseases, National Institutes of Health, Bethesda, Maryland;
2Department of Medicine, Albert Einstein College of Medicine, Bronx, New York
Abstract.]

Eternacept used as a steroid sparing agent –
Quite successful
More studies needed!

59



60



61

62

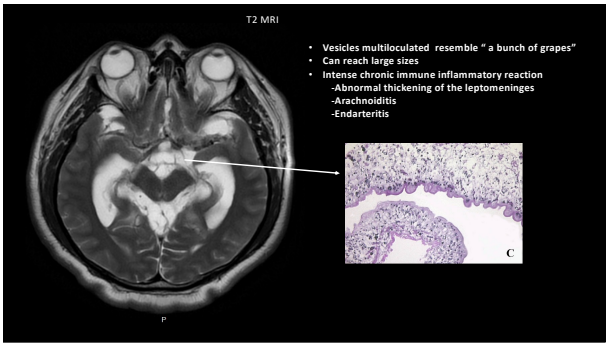

63

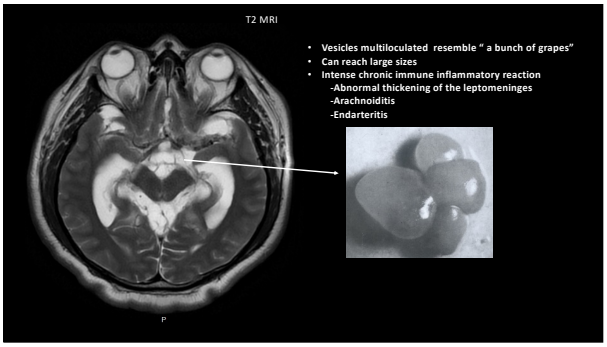

64

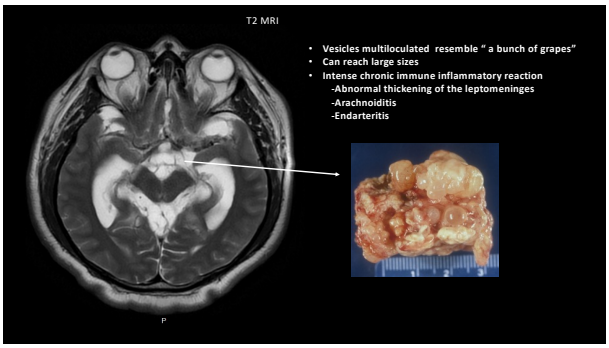

65

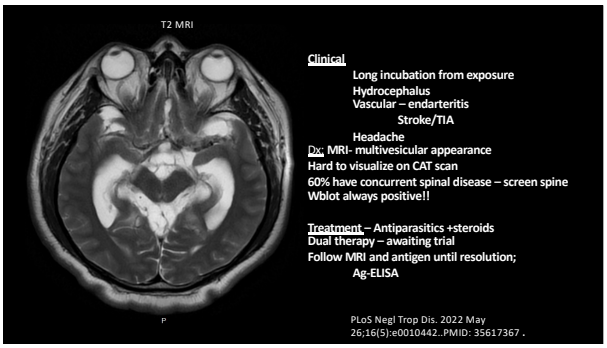

66

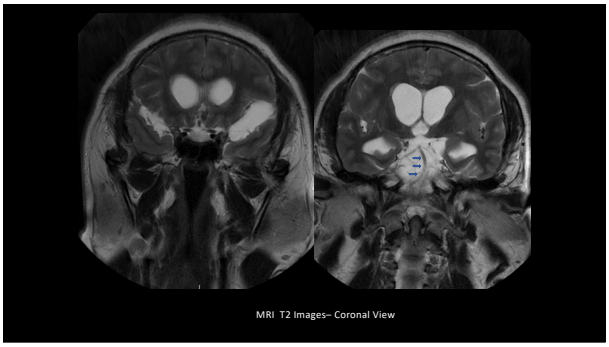

67

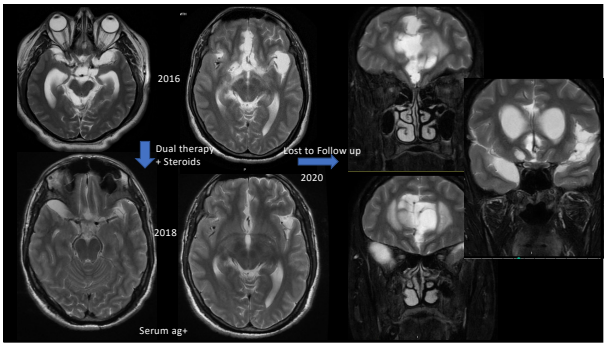

68

Hydrocephalus is common!

69

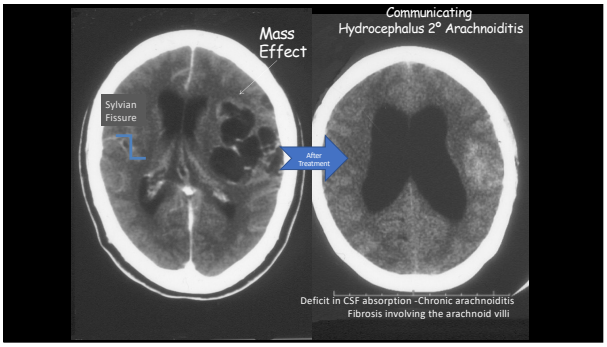

70

Hydrocephalus- Obstructive

- Occlusion of Luschka's/Magendie's foramina
  Thickened leptomeninges
- Exacerbated inflammation accompanying the presence of the parasite is generally the primary triggering factor !!!!

71

Vascular Involvement

72

The patient is an 18 year old male born in El Salvador. The patient immigrated when he was 10 years old. He was in his usual state of health when he fell to the floor and could not get up due to right sided hemiplegia. Labs WNL, Chest X-ray normal. An MRI was performed….

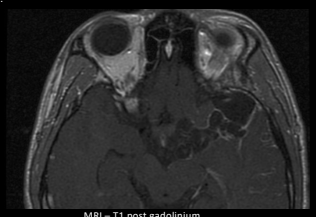

MRI – T1 post gadolinium

Multiple cystic thin walled lesions in the pre-pontine cisterns and Sylvian fissure with enhancement consistent with neurocysticercosis.

73

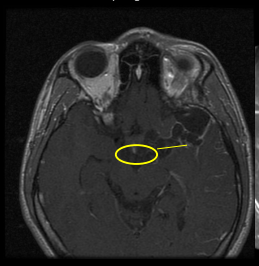

MRI – T1 post gadolinium

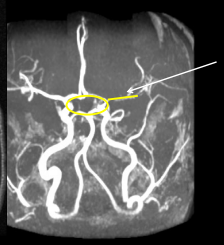

MRA – 1st branch of MCA occluded

74

Vascular Involvement Endarteritis

- Ischemic
  - Usually small vessel – lacunar infarcts
    - MRA/angiogram can be negative
  - Large vessel disease can occur
  - Occur on presentation or during the taper of steroids
- Hemorrhage
  - Rare – usually on presentation
- Needs high dose steroids with careful taper

Arch Neurol. 1996 Mar;53(3):233-9. doi: 10.1001/archneur.1996.00550030039021.

75

Screen the spine!

76

28 patients basal subarachnoid disease
17 had concurrent spinal disease (60%)
LS involved 89%
Nash et al. Neurology 2012 May 1;78(18):1394

77

So…that was a lot. How do you manage this disease….

- Screen the spine, eye - get quantiferon, strongyloides
- Immunoblot should be positive
- Start high dose prednisone
  - 60-80 mg for a 1-2 weeks
  - 40 mg and then taper 1 mg per week
- Dual therapy with albendazole/praziquantel
  - If possible
- Image every 3 months (or earlier if symptoms)
- Obtain and follow the recombinant antigen
- Treatment can be months and greater than a year
- Recurrences can occur
- CLOSE follow up

78

INTRAVENTRICULAR NEUROCYSTICERCOSIS (IVNC)

79

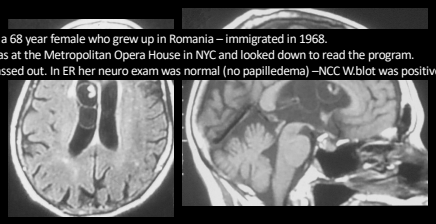

This is a 68 year female who grew up in Romania – immigrated in 1968.
She was at the Metropolitan Opera House in NYC and looked down to read the program.
She passed out. In ER her neuro exam was normal (no papilledema) –NCC W.blot was positive.

80

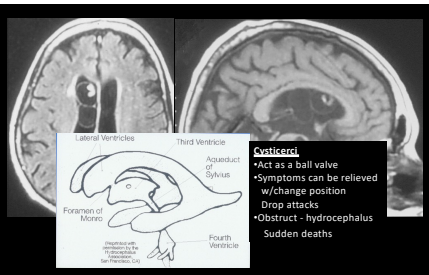

Cysticerci
- Act as a ball valve
- Symptoms can be relieved w/change position
  Drop attacks
- Obstruct - hydrocephalus
  Sudden deaths

81

A 32-year- old Pregnant Woman from Ecuador with a Headache

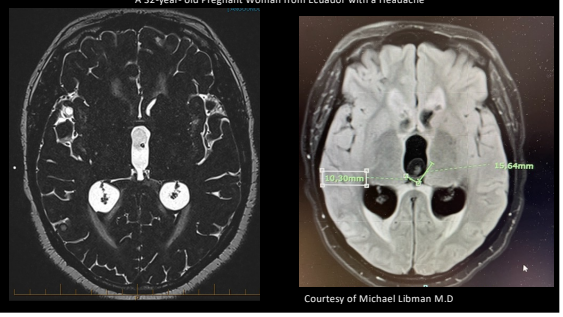

Courtesy of Michael Libman M.D

82

83

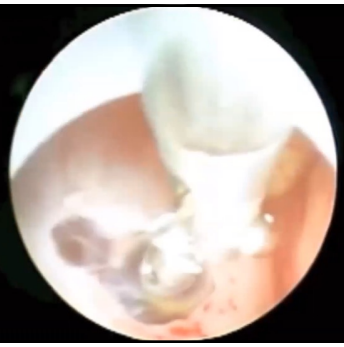

84

85

Intraventricular NCC (IVN)

MRI with 3D volumetric sequencing over other imaging modalities to identify intraventricular and subarachnoid cysticerci in patients with hydrocephalus and suspected cysticercosis (strong, moderate)

- **Optimal approach to management of IVN in the lateral and third ventricles**

  Recommendation:

  Removal of the cysticerci by minimally invasive, neuroendoscopy (Strong, moderate).

  Remark: Anti-parasitic drugs should not be used preoperatively, since they provide no benefit and can interfere with successful cyst removal

- **Optimal surgical approach to management of IVN in the fourth ventricle**

  Recommendation

  Recommend surgical removal rather than medical therapy and/or shunt surgery (strong, moderate).

- **Optimal approach to adherent IVN**

  Recommendation

  Shunt surgery for hydrocephalus rather than cyst removal when surgical removal is technically difficult (weak, low).

  Remark: Attempted removal of inflamed or adherence ventricular cysticerci is associated with increased risk of complications.

  Anti-parasitic drugs along with corticosteroids after shunt insertion to decrease subsequent shunt failure in patients in whom surgical removal of isolated intraventricular cysts is not possible (weak, low)

Intraventricular Neurocysticercosis: Experience and Long-Term Outcome from a Tertiary Referral Center in the US.
Nash et al. Am J Trop Med Hyg.,98(6),2018 pp. 1755-1762

86

Pearls!
NCC is a pleomorphic disease

- Parenchymal Disease – viable
  - > 2 lesions – albendazole/praziquantel plus steroids
  - 1-2 lesions – albendazole plus steroids
  - Longer tx steroids – less seizures
- Parenchymal Disease – calcified disease
  - Implicated in ongoing seizures
  - Perilesional edema occurs
  - No antiparasitic treatment – try to avoid steroids
- Extraparenchymal disease
  - Intraventricular Disease
    - Endoscopic removal 3rd and lateral ventricle
  - Subarachnoid Disease
    - Dual therapy – longer courses of antiparasitic and slow taper steroids
      - Follow MRI, antigen/PCR to define treatment endpoints.
    - Commonly associated with spinal disease – screen the spine

87

References

- Diagnosis and Treatment of **Neurocysticercosis**: 2017 Clinical Practice Guidelines by the Infectious Diseases Society of America (IDSA) and the American Society of Tropical Medicine and Hygiene (ASTMH).White AC Jr, Coyle CM, Rajshekhar V, Singh G, Hauser WA, Mohanty A, Garcia HH, Nash TE.Clin Infect Dis. 2018 Apr 3;66(8):e49-e75. PMID: 29481580
- Subarachnoid **neurocysticercosis**: emerging concepts and treatment.Nash TE, O'Connell EM.Curr Opin Infect Dis. 2020 Oct;33(5):339-346. PMID: 32868512
- **Disease** Centered Around Calcified Taenia solium Granuloma.Nash TE, Bustos JA, Garcia HH; Cysticercosis Working Group in Peru.Trends Parasitol. 2017 Jan;33(1):65-73.PMID: 27720140
- Efficacy of combined antiparasitic therapy with **praziquantel** and albendazole for **neurocysticercosis**: a double-blind, randomised controlled trial.Garcia HH, Gonzales I, Lescano AG, Bustos JA, Zimic M, Escalante D, Saavedra H, Gavidia M, Rodriguez L, Najar E, Umeres H, Pretell EJ; Cysticercosis Working Group in Peru.Lancet Infect Dis. 2014 Aug;14(8):687-695. doi: 10.1016/S1473-3099(14)70779-0. Epub 2014 Jul 3.PMID: 24999157
- **Neurocysticercosis** as a cause of **stroke**.Barinagarrementeria F, Cantú C.Stroke. 1992 Aug;23(8):1180-1. PMID: 1636197
- **Intraventricular Neurocysticercosis**: Experience and Long-Term Outcome from a Tertiary Referral Center in the United States.Nash TE, Ware JM, Mahanty S.Am J Trop Med Hyg. 2018 Jun;98(6):1755-1762. doi: 10.4269/ajtmh.18-0085. Epub 2018 Apr 19.PMID: 29692305
- Natural History of Treated Subarachnoid **Neurocysticercosis**.Nash TE, O'Connell EM, Hammoud DA, Wetzler L, Ware JM, Mahanty S.Am J Trop Med Hyg. 2020 Jan;102(1):78-89. doi: 10.4269/ajtmh.19-0436.PMID: 31642423

88

Echinococcus: Cases that Blur the Line

89

Staging Hepatic CE

90

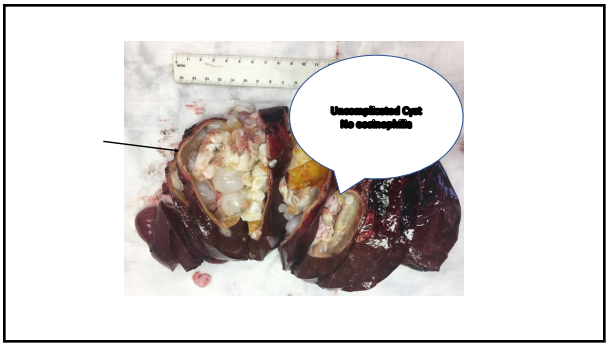

91



92

93

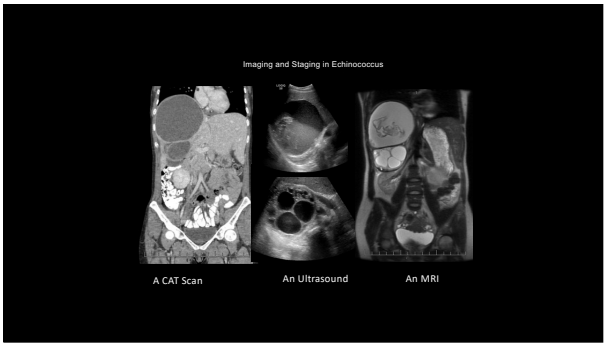

94

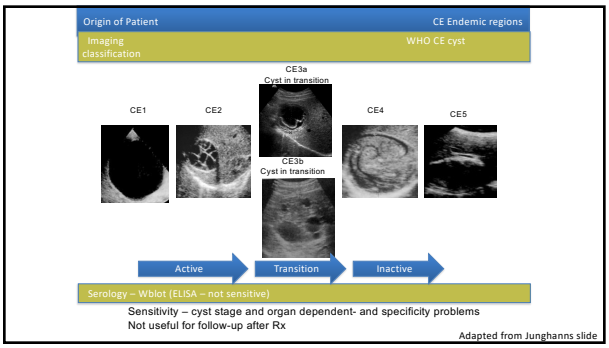

95

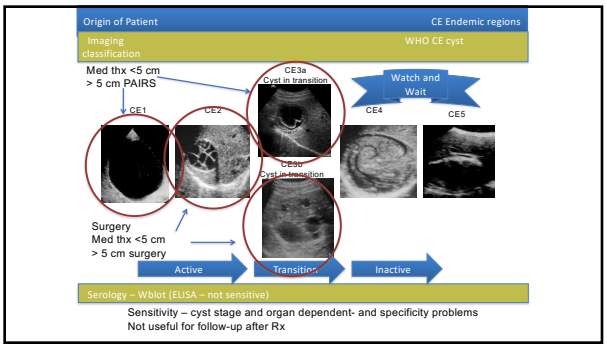

96

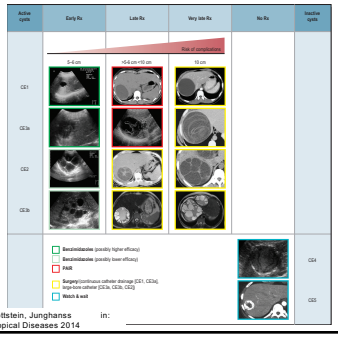

97



98

WHO recommendations

- CE 1/CE3a
  - < 5 cm can treatment with albendazole
  - >5 cm and less than 10 cm – PAIR (Percutaneous Drainage and Re-instillation of a Scolicidal Agent) PLUS Albendazole
    - Do not perform if there is biliary communication
  - >10 cm uncomplicated – PAIR
    - I would be careful!
- CE2/CE3b
  - <5 cm can treat with albendazole
  - > 5 cm surgery
- CE4/5 Watch and wait

99

100

101

102

CE1 and CE3a

103

A Religious Pilgrimage….

104

- 19-year-old male born in the United States.
- Only travel to Iraq and Iran towards the end of 2015
  - A one-night layover in Istanbul.
  - Each time, he stayed in hotels with his family.
- Well until November 2020 - began experiencing diffuse pruritis.
  - It was not associated with any rash or new medications.
- A few weeks later, the patient noticed:
  - Yellow discoloration of his skin and eyes
  - Weight loss of around 20 lbs
- On 12/18, the patient had bloodwork done with his PCP:
  - WBC: 6.13 with 13% eosinophils
  - Alk phosphatase 812, T. bili 3.7, AST 288, ALT 464

105

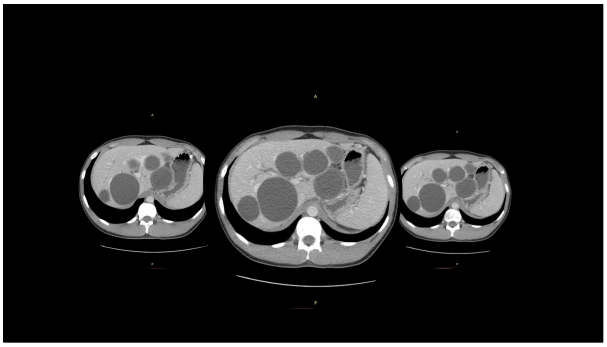

106

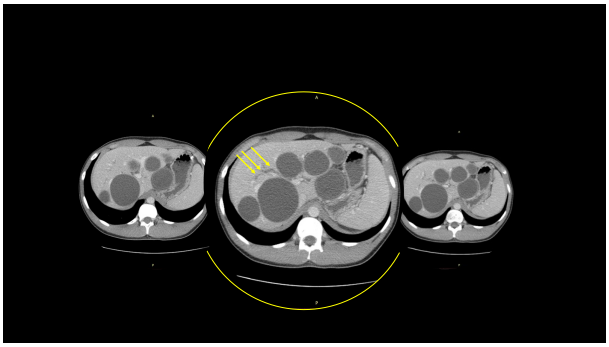

107

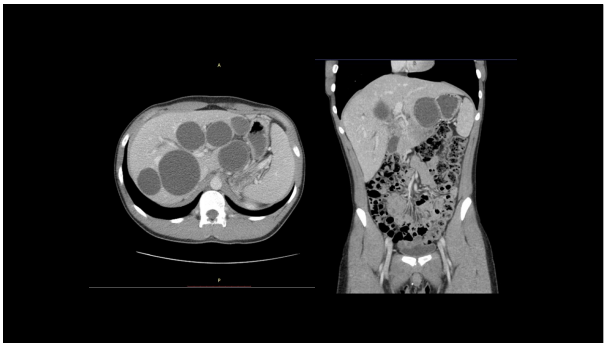

108

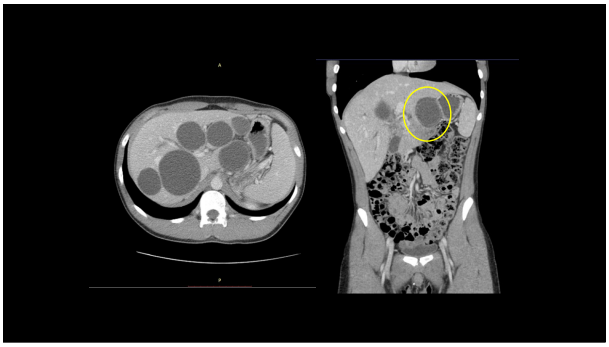

109

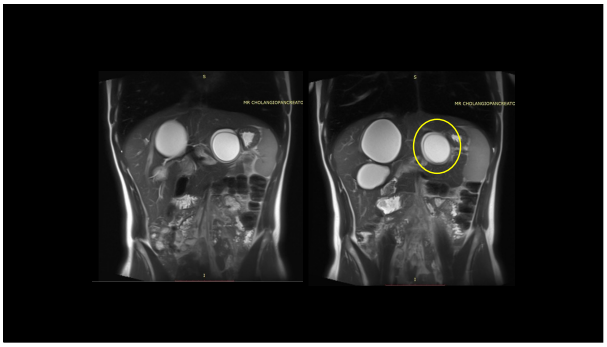

110

MRCP Report 12/23/2020

Multiple hepatic cysts with largest measuring 7.2 cm in segment 7. Segment 2 lesion is ~ 3cm and mildly T1 hypointense and T2 isotense. Segment 3 lesion is 2.7cm and demonstrates heterogenous T1 hypointensity and T2 hyperintensity, no evidence of enhancement. Mild prominence of intra-hepatic ducts, probably secondary to compression from above lesions.

111

How did he get this??????

112

WHO recommendations

- CE 1/CE3a
  - < 5 cm can treatment with albendazole
  - >5 cm and less than 10 cm – PAIR (Percutaneous Drainage and Reinstillation of a Scolicidal Agent) PLUS Albendazole
    - Do not perform if there is biliary communication
  - >10 cm uncomplicated – PAIR
    - I would be careful!
- CE2/CE3b
  - <5 cm can treat with albendazole
  - > 5 cm surgery
- CE4/5 Watch and wait

113

Back to our patient…. Sent him to the OR

114

115

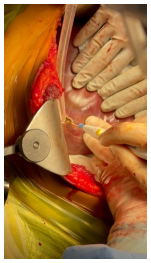

116

117

His twin brother traveled with him..
Asymptomatic. We decided to screen him.

118

119

US Report 1/25/21

- Findings:
- Liver - Large cyst with discernible wall measuring 9.5 x 7.6 cm. No internal structure. No septations or internal locules.
- Bile ducts: Normal caliber. Common bile duct measures 4mm.
- Gallbladder: Within normal limits.
- Pancreas: Poorly visualized.
- Spleen: 10.3cm, within normal limits.
- Right kidney: 9.3cm. No hydronephrosis.
- Left kidney: 10.9cm. No hydronephrosis.
- Ascites: None.
- Aorta and IVC: Visualized portions are within normal limits.

120

121

PAIRS:Who to treat

Expert Consensus,WHO

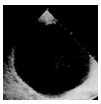

- Inoperable patients
- Best results - >5cm-<10cm CE1 and CE3a cysts
- In pregnant women w/ symptomatic cysts

Contraindications

- Lung Cysts
- Biliary fistulae
- Proximity to vascular structures
- Peripheral cysts – do not have adequate hepatic tissue

122

Back to our patient… he now has urticaria….

123

124

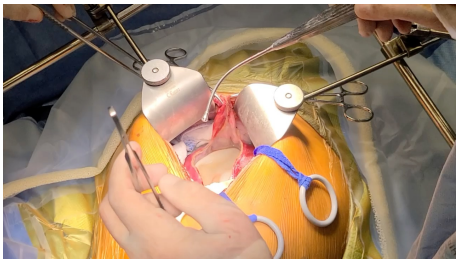

125

Lessons Learned

- Echinococcus can occur in short term travelers.
- Must dig into behavior of traveler.
- Latency was 5 years in these patients!!! Amazing
- A negative MRCP does not rule out biliary communication.
- CE1 large peripheral cysts should go to surgery (>10 cm)
- Staging and individualized therapy is crucial.

126

Management of CE3b

127

A 62 year old Italian Immigrant
with abdominal pain. Treated with albendazole – no change

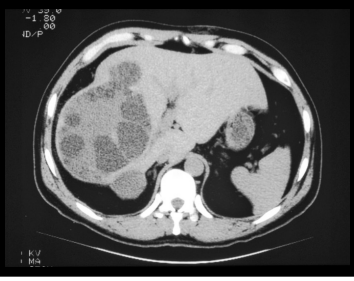

128

WHO recommendations

- CE 1/CE3a
  - < 5 cm can treatment with albendazole
  - >5 cm and less than 10 cm – PAIR (Percutaneous Drainage and Reinstillation of a Scolicidal Agent) PLUS Albendazole
    - Do not perform if there is biliary communication
  - >10 cm uncomplicated – PAIR
    - I would be careful!
- CE2/CE3b
  - <5 cm can treat with albendazole
  - > 5 cm surgery
- CE4/5 Watch and wait

129

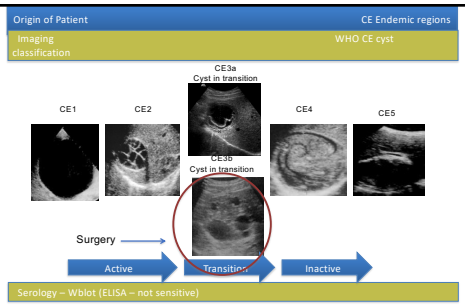

Sensitivity – cyst stage and organ dependent- and specificity problems
Not useful for follow-up after Rx

130

PERCUTANEOUS DRAINAGE VS. SURGERY FOR HEPATIC HYDATID CYSTS

PERCUTANEOUS DRAINAGE COMPARED WITH SURGERY FOR HEPATIC HYDATID CYSTS

Mohammad Sultan Khuroo, D.M., Nazir A. Wani, M.S., Gul Javid, M.D., Bashir A. Khan, M.D., Ghulam N. Yattoo, M.D., Altaf H. Shah, M.D., and Samoon G. Jeelani, M.D.

Abstract

Background In recent years percutaneous drainage has been used successfully to treat the hepatic hydatid cysts of echinococcal disease. We performed a controlled trial to compare the safety and efficacy of percutaneous drainage with those of surgical cystectomy, the traditional treatment.

Methods In a prospective study, we randomly assigned 56 patients with hepatic hydatidosis to treatment with percutaneous drainage (25 patients) or cystectomy (25). Albendazole (10 mg per kilogram of body weight per day for eight weeks) was administered to the patients who underwent percutaneous drainage. Serial assessments included clinical and biochemical examinations, ultrasonography, and serologic tests of echinococcal-antibody titers.

Results The mean (±SD) hospital stay was 4.2±1.5 days in the drainage group and 12.7±6.5 days in the surgery group (P<0.001). Over a mean follow-up period of 17 months, the mean cyst diameter decreased from 8.0±3.0 to 1.4±3.5 cm (P<0.001) after percutaneous drainage and from 9.1±3.0 to 0.9±1.8 cm (P<0.001) after surgery. The final cyst diameter did not differ significantly between the two groups (P=0.20). The cysts disappeared in 22 patients (88 percent) in the drainage group and in 18 (72 percent) in the surgery group (P=0.29). After an initial rise, the echinococcal-antibody titers fell progressively in both groups. Recurrence occurred in 19 patients (76 percent) in the drainage group and 17 (68 percent) in the surgery group (P=0.74). There were procedure-related complications in 8 patients (32 percent) in the drainage group and 21 (84 percent) in the surgery group, 17 of whom had fever postoperatively (P<0.001).

South America, and northern Kenya.[2] With immigration, the prevalence of the disease has increased in Europe and North America.

The most frequent site of hydatid cysts is the liver (accounting for 50 to 70 percent of cases), followed by the lungs (20 to 30 percent), and less frequently, the spleen, kidneys, heart, bones, central nervous system, and elsewhere. Cystic echinococcosis is usually asymptomatic, but a substantial number of infections cause morbidity, with occasional mortality. Hepatic hydatid cysts can rupture into the peritoneum, leading to anaphylaxis or peritoneal dissemination or both; into the biliary tract, causing cholangitis or cholestasis or both; or into the pleura or lung, causing pleural hydatidosis or bronchial fistula. Cysts may become infected and form liver abscesses. Pressure or mass effects on the bile ducts, portal veins, and hepatic veins and inferior vena cava can cause cholestasis, portal hypertension, and the Budd–Chiari syndrome, respectively.[3-8]

Surgery is the recommended treatment for hepatic hydatid cysts.[3] However, drug therapy and percutaneous drainage have recently been introduced as alternative treatments.[9] Two benzimidazoles (mebendazole and albendazole) have scolicidal activity but are clinically effective in less than 30 percent of patients with hepatic hydatidosis.[9-12] Percutaneous drainage is minimally invasive and very effective in the treatment of hepatic hydatidosis.[13-16] Studies of large numbers of patients followed for up to five years have shown that the risk of anaphylaxis is negligible, and regrowth of cysts does not occur.[15-17] We previously performed a prospective, randomized trial

131

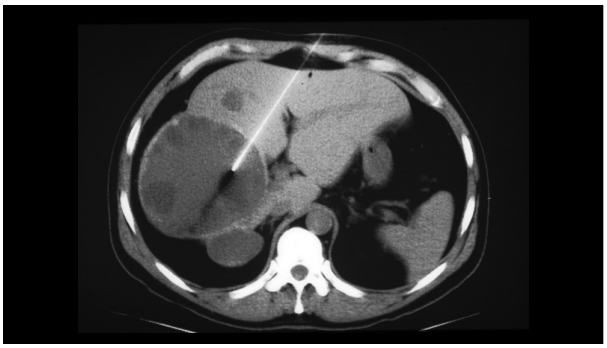

132

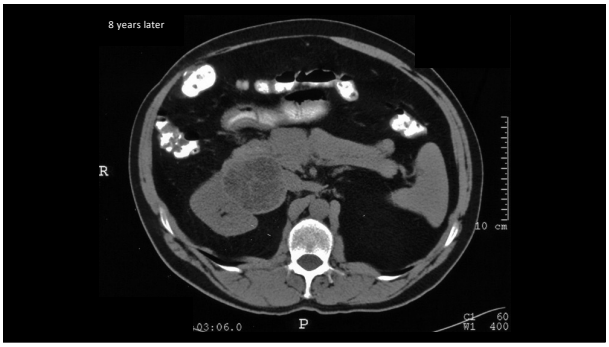

133

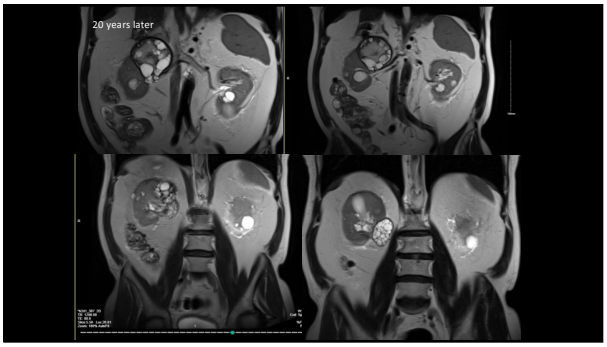

134

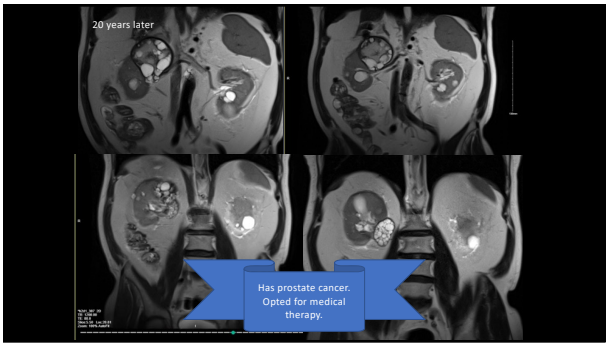

135

Stage and Choose Wisely
Follow for Recurrences!

136

CE4/CE5

137

138

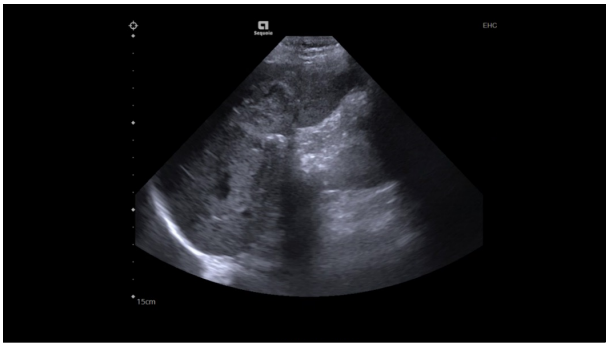

139

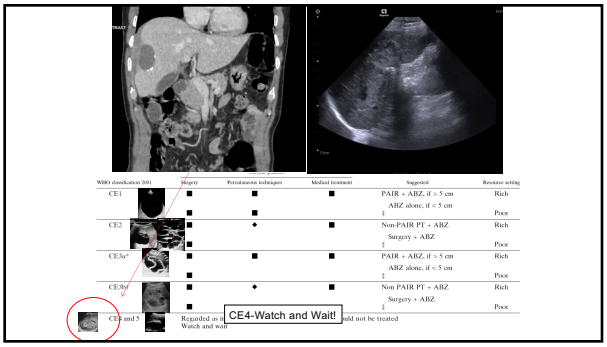

140

141

142

143

Rupture….

144

A Case of Rupture

The patient is a 37 year old male born in Ibb, Yemen.

He notes that in the am he started feeling dizzy and sweaty and thought it was low blood pressure. Later in the day he went out to dinner he felt cold, sweaty and dizziness. He also noted that he had excruciating abdominal pain. He did not have difficulty breathing. No rashes. He went home and was not able to move. EMS was called.

Yemen - Grew up in Ibb - 3-4 dogs in the house in Ibb. Bathroom in the house.

145

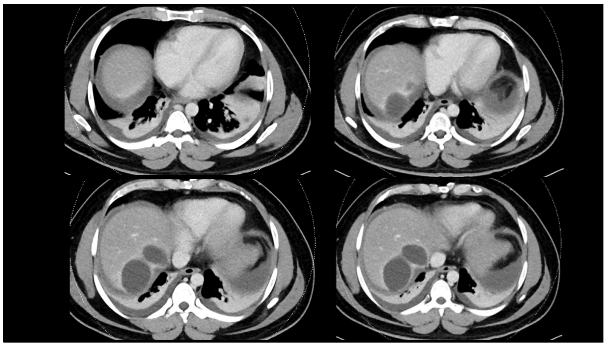

146

147

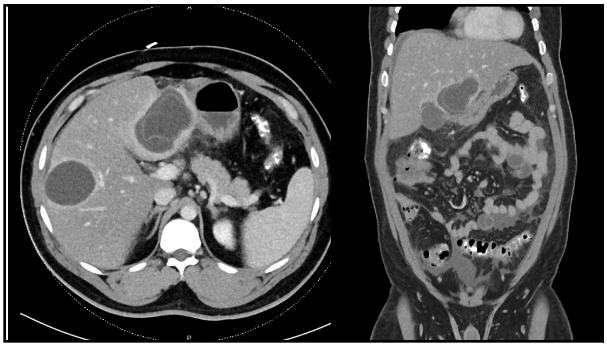

148

Lymphocyte %	14.0 ⌄
Monocyte %	3.9 ⌄
Eosinophil %	23.2 ^
Basophil %	0.7
Imm Gran %	2.5 ^
Neutrophil Abs	8.17 ^
Lymphocyte Abs	2.05
Monocyte Abs	0.57
Eosinophil Abs	3.39 ^
Basophil Abs	0.10
Immature Gran Abs	0.36 ^
NRBC Abs	0.00

149

Ref Range & Units (hover)

WBC	14.64 ^
RBC	5.61
Immunoglobulin E	2879 ^

Comment: Entire Orderable Performed at:
Northwell Health Laboratories
450 Lakeville Road
Lake Success, NY 11042-1110
Orderable--Immunoglobulin E

RDW	13.3
PLT	325
Neutrophil %	55.7

150

Albendazole plus Praziquantel vs Albendazole Alone – Intra-Abdominal Hydatidosis

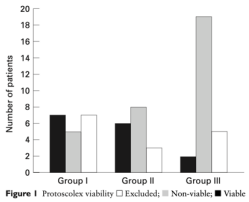

Figure 1 Protoscolex viability ☐ Excluded; ▒ Non-viable; ■ Viable

Group 1 (June 1990- February 1992): 19 patients; received albendazole 10 mg/kg/day.
Group 2 (March 1992-September 1994): 17 patients; received albendazole 20 mg/kg/day.
Group 3 (October 1994-July 1997): 26 patients; received albendazole 10 mg/kg/day plus praziquantel 25 mg/kg/day.

Tropical Medicine and International Health
VOLUME 3 NO 6 PP 462–466 JUNE 1998

151

Complications

152

A 23 year old exchange student from Turkey presented with abdominal pain.

153

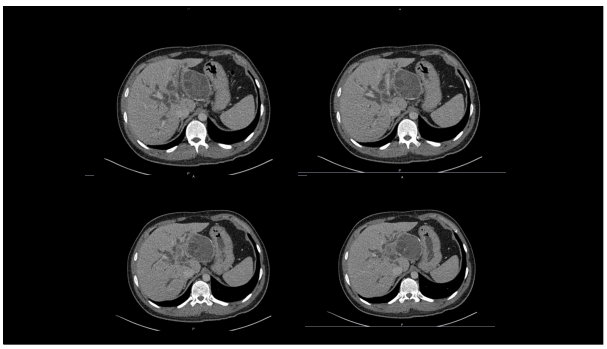

154

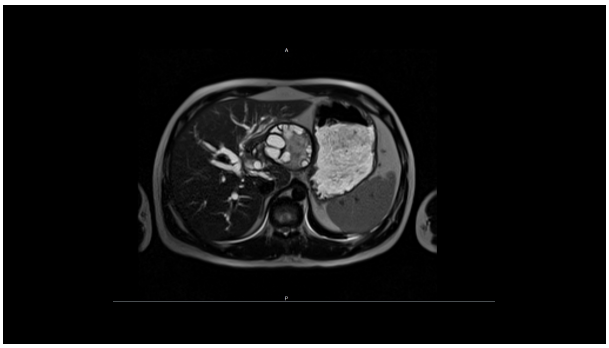

155

Left Hepatectomy

156

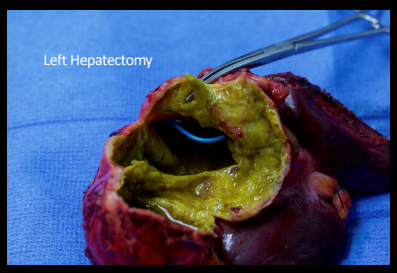

157

Biliary Communication with the Cyst

- Surgery
- ERCP
- Avoid hypertonic saline/ETOH
- Complication - superinfection

158

A 52 year old woman from Southern India was seen for abdominal pain. She was Told her cyst was inactive and there was nothing to do.

159

Five years later she presented with intermittent right upper quadrant pain for a few weeks. Began having chills and worsening RUQ pain and fever. Elevated WBC and high fever. Toxic appearing

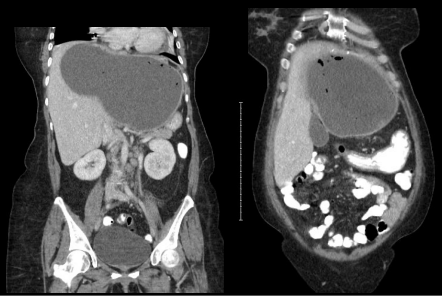

160

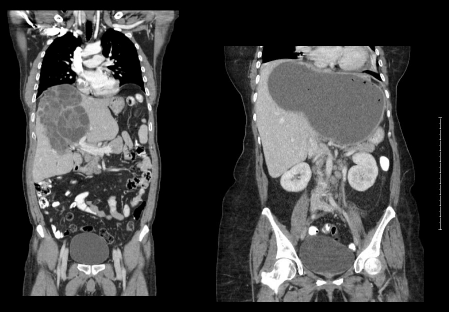

161

Summary:
Communication with the Biliary Tree

- Take a good history
- Rule out prior to surgery/PAIRS
- MRCP/ERCP
- In procedure – check bilirubin
- Work hand in hand with your surgeon
- NO HYPERTONIC saline!

162

Another Case

34-year-old female from Bulgaria with past medical history of urticaria. She has been experiencing back pain for 10 years. She had an US which showed cystic masses in the liver and peritoneum. An MRI was done that revealed the presence of retroperitoneal cysts and ? Ovarian cyst.

163

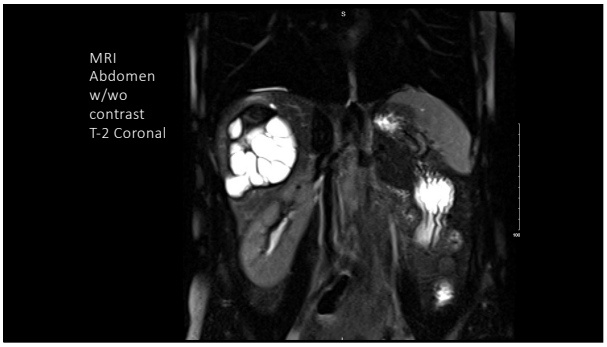

164

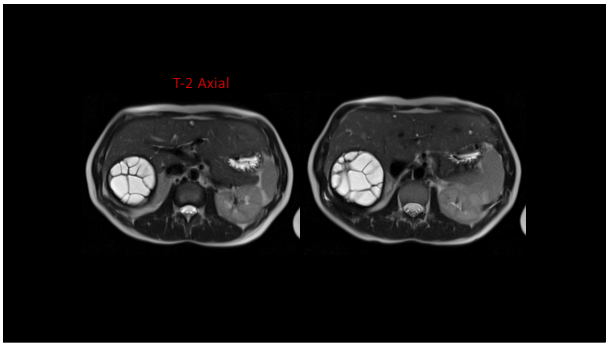

165

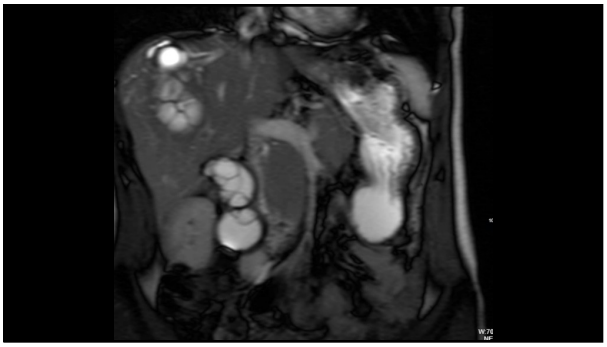

166

167

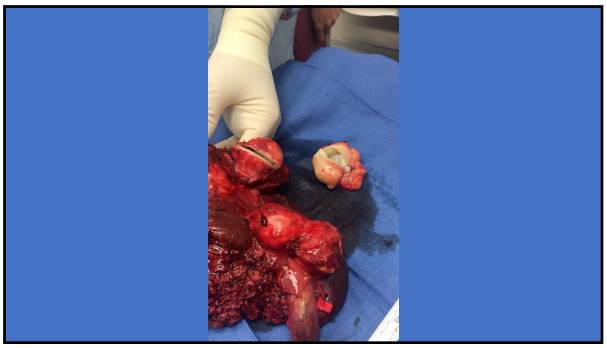

168

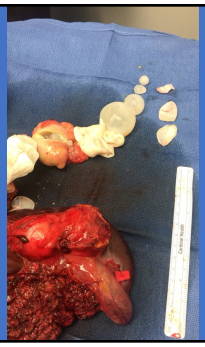

169

170

Learning Points

- Multi-disciplinary teams
- Intra-op collaboration

171

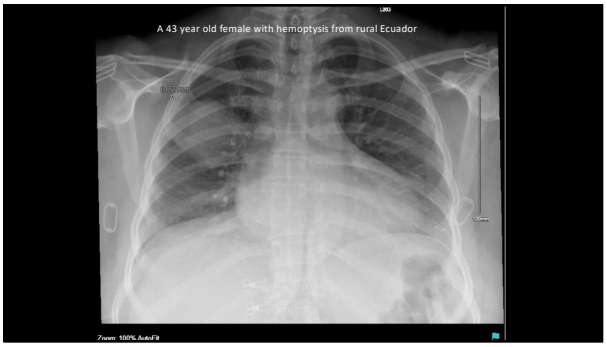

172

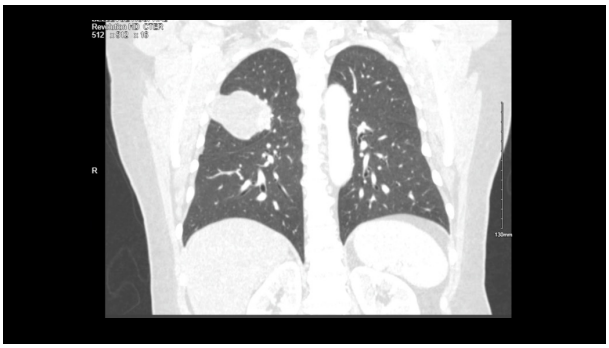

173

Common Presenting Symptoms of Pulmonary Hydatid Disease

- Asymptomatic (68%)
- Hemoptysis, cough,dyspnea
- Pulmonary cysts rupture into bronchi
  - Formation of cystobronchial fistula
  - "Salty water and grape skin" expectoration
- Cyst rupture into pleural space
  - Pleural effusion
- Ruptured cysts may become infected
  - Bacteria or saprophytic fungi

174

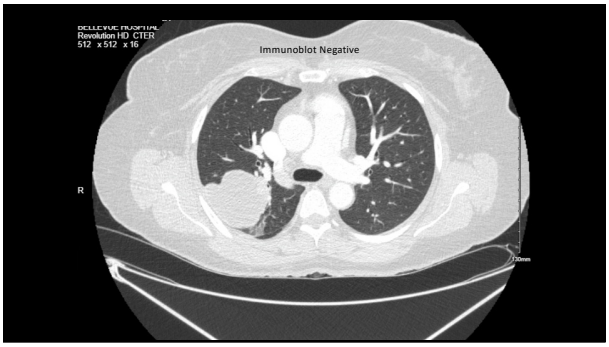

175

Three months later….

176

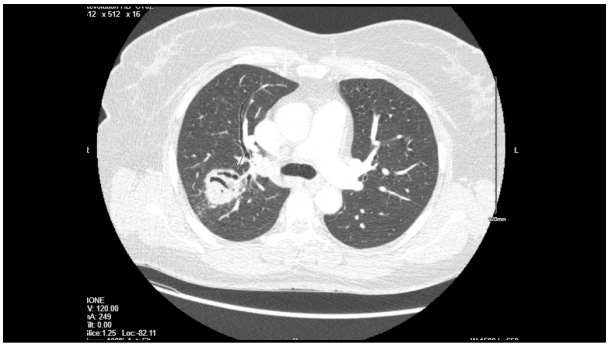

177

Cystobronchiolar Fistula

Whirl Sign
Collapsed Membranes

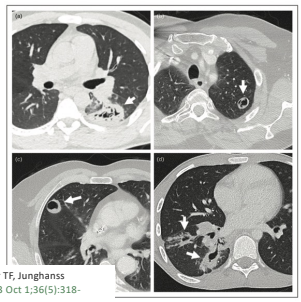

Pulmonary cystic echinococcosis.Weber TF, Junghanss T, **Stojković M.**Curr Opin Infect Dis. 2023 Oct 1;36(5):318-325.PMID: 37578473

178

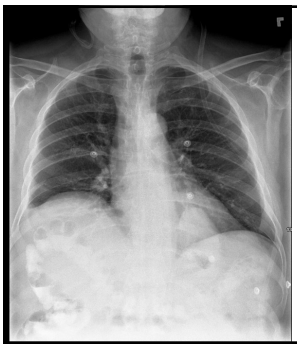

An 80 year old from Ecuador with abdom
Pain. Found an incidental cyst on CXRY.

179

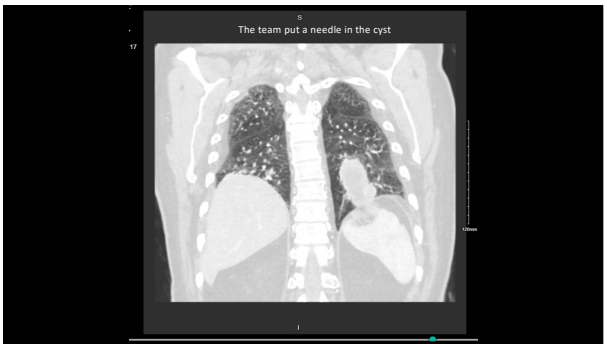

180

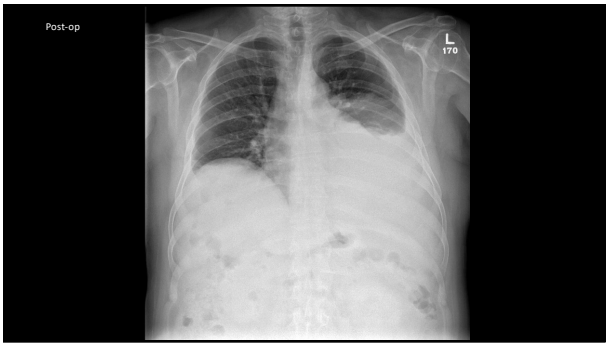

181

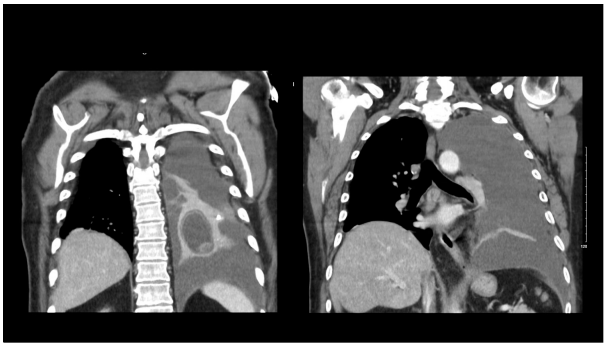

182

Pulmonary Cystic Echinococcus

- Surgery is the mainstay of treatment for pulmonary cystic echinococcosis.
- Frequently, patients with cystic echinococcosis have lung and liver cysts.
  - In these instances, a sequential surgical approach starting with surgery of lung cysts because of the higher probability of cyst rupture, cystobronchial fistula and associated complications is appropriate.
- For pulmonary cystic echinococcosis surgery, double lumen intubation is obligatory in order to prevent spillage of cyst content to the healthy lung during surgery.
- Lung parenchyma sparing surgical techniques with partial cystectomy (formerly 'endo- cystectomy') should be applied whenever possible.

183

KEY POINTS

- Never exclude pulmonary cystic echinococcosis on the basis of negative serology.
- Never do a cyst puncture if you suspect pulmonary cystic echinococcosis.
- Medical treatment with albendazole is used for periinterventional treatment of pulmonary cysts and started only 1–2 days prior to surgery to not induce complications.
- Parenchyma-sparing surgical techniques should be used whenever possible.

184

Echinococcal Disease Summary

- Diagnosis requires imaging and staging of disease
- Therapy needs to be individualized

185

References

- Clinical management of **cystic echinococcosis**: state of the art and perspectives.**Stojković M**, Weber TF, Junghanss T.Curr Opin Infect Dis. 2018 Oct;31(5):383-392. PMID: 30124496
- Pulmonary **cystic echinococcosis**.Weber TF, Junghanss T, **Stojković M.**Curr Opin Infect Dis. 2023 Oct 1;36(5):318-325.PMID: 37578473

Standardized endocystectomy technique for surgical treatment of uncomplicated hepatic **cystic echinococcosis**.Al-Saeedi M, Khajeh E, Hoffmann K, Ghamarnejad O, **Stojkovic M**, Weber TF, Golriz M, Strobel O, Junghanss T, Büchler MW, Mehrabi A.PLoS Negl Trop Dis. 2019PMID: 31226109

186

187